



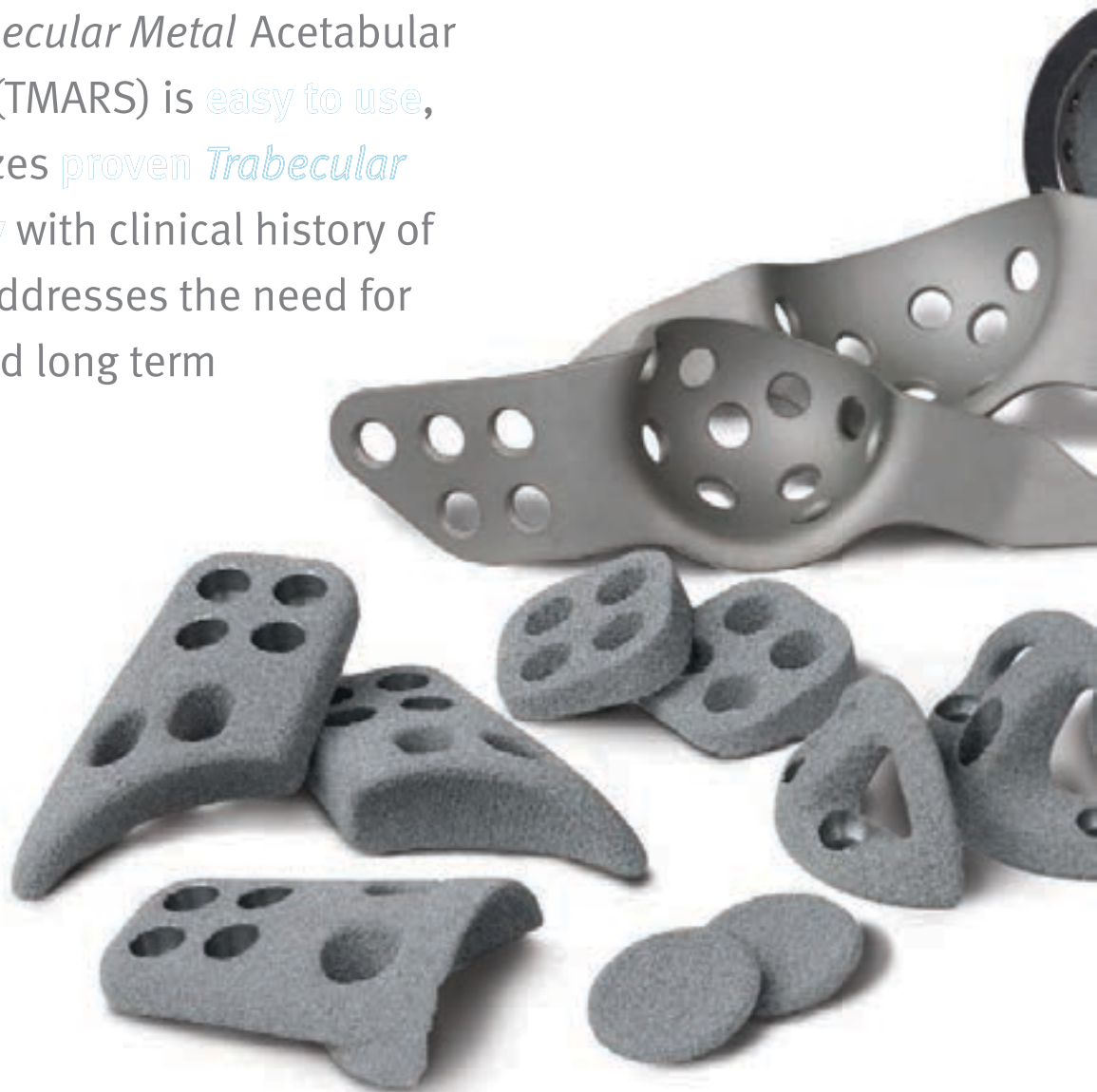Zimmer®
Trabecular Metal™
Acetabular Revision
System
(TMARS)

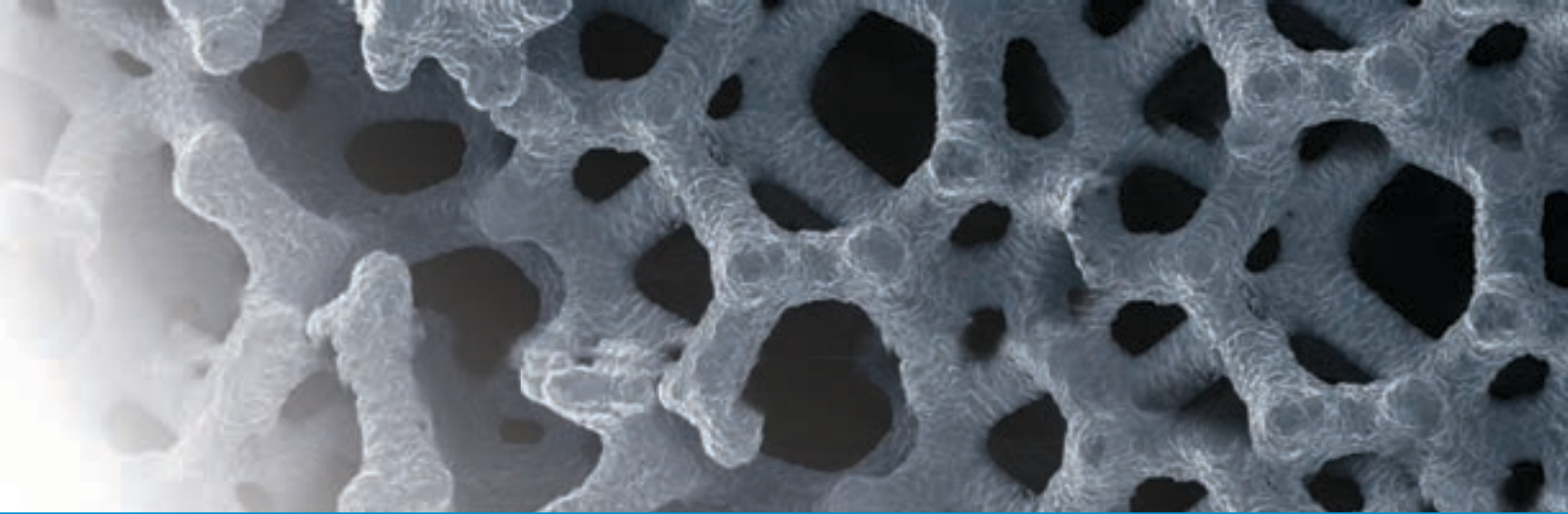


Zimmer Trabecular Metal Acetabular Revision System

Approach Acetabular Revision Cases with Confidence

For surgeons who want to treat acetabular defects,¹ the *Trabecular Metal* Acetabular Revision System (TMARS) is **easy to use**, **durable** and utilizes **proven Trabecular Metal Technology** with clinical history of 17+ years.¹⁹⁻²¹ It addresses the need for initial stability and long term biologic fixation.





Easy to Use

No Structural Allograft Preparation

The need for allograft bone preparation is virtually eliminated, saving precious surgical time.

One Comprehensive Modular System

The *Trabecular Metal* Modular Acetabular Revision System (TMARS) has the flexibility for mixing and matching implants intraoperatively enabling more efficient case management and execution in the OR relative to what other implant systems can offer.^{3-5,11} Important time savings is realized before and during surgery.



Trabecular Metal Revision Shells & Liners

- *Trabecular Metal* Material allows excellent cement interdigitation between liner and revision shell
- Cemented liner allows for placement at the exact coverage angle and has a grooved backside to provide rotational stability



Trabecular Metal Augments

- Interfaces are cemented against the *Trabecular Metal* Revision Shell, creating a monolithic construct without concerns of micromotion



Trabecular Metal Cup-Cage Constructs

- Cage can be contoured to fit the acetabulum while providing mechanical stability of the Cup-Cage construct until biological ingrowth occurs within the *Trabecular Metal* Revision Shell



Trabecular Metal Buttress & Shim Augments

- Sizing allows use with *Trabecular Metal* Revision Shells of any size
- Shims placed between Buttress Augment flange and host bone optimize the fit of the device against the iliac bone

Durable

No Graft Resorption

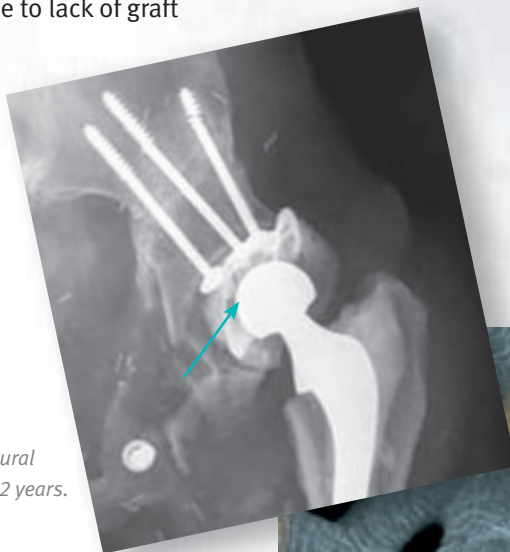
Use of TMARS eliminates the concern about graft vascularization and resorption and eventual collapse. This also eliminates the need for a future revision due to lack of graft incorporation.

No Disease Transmission

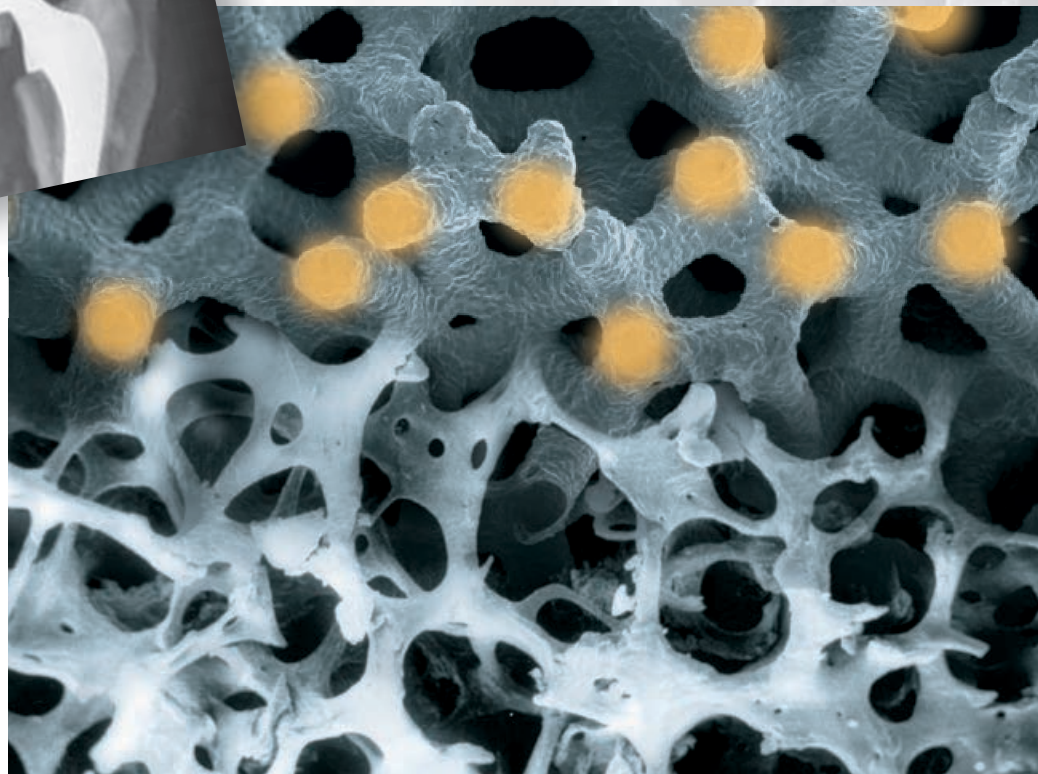
Use of TMARS alleviates concerns about disease transmission that may be caused by use of a donor graft.

Great Potential for Biologic Ingrowth⁶⁻⁹

Trabecular Metal Technology offers a high coefficient of friction which helps reduce micromotion, enabling tissue growth. Its 3D construct provides a high level of porosity and potential for osteoconductivity allows for more rapid in-growth supporting a vascularized structure to maintain healthy bone. Implant durability leads to longevity and reduced risk for future surgeries.



Failure of structural allograft after 12 years.

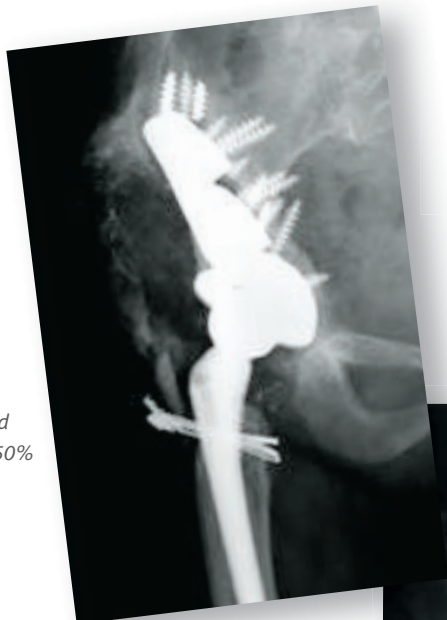
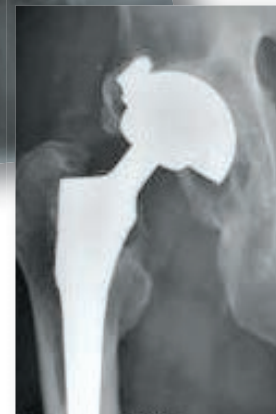
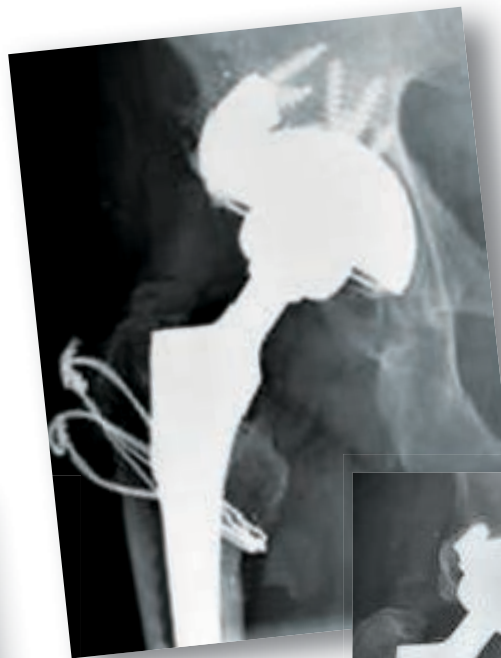

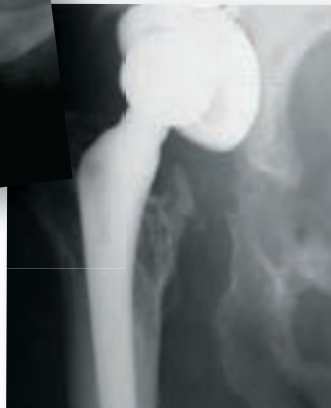Proven Technology

Clinical Success

Trabecular Metal Technology has more than 17 years of clinical history with orthopaedic implants and over 75 peer-reviewed journal publications have been issued, providing additional confidence in this technology.¹⁹⁻²¹



Pre-Op: Uncontained Segmental Defect, >50% of Acetabulum

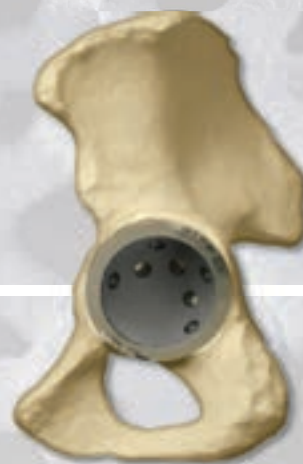

Pre-Op: Uncontained Segmental Defect, >50% of Acetabulum

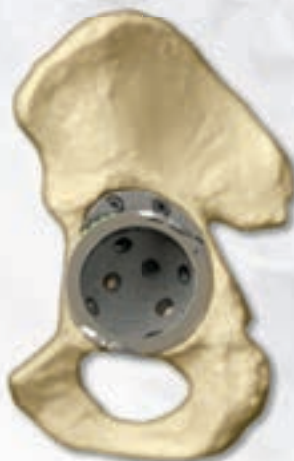Pre-Op: Uncontained Bone Loss, <50% of Acetabulum

Full Range of Revisions Successfully Treated^{1,2,12,16-18}

An array of revision cases ranging from simple to extremely complex has been effectively treated with *Trabecular Metal* implants. Defects spanning Paprosky Type I through IV have been successfully treated with the *Trabecular Metal* Acetabular Revision system.



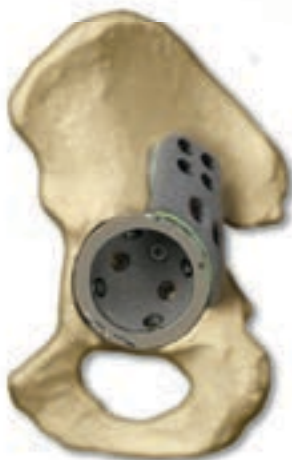Type I & Type II
Defects



Type IIIA
Cavitory Defect



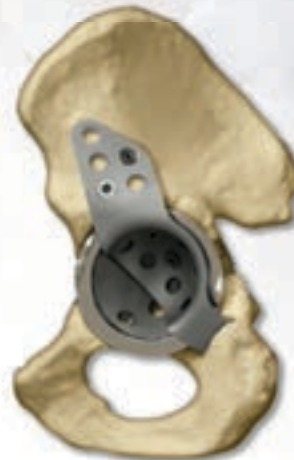Type IIIA
Segmental Defect



Type IIIA
Extensive Segmental Defect



Type IIIB
Contained Medial Defect



Pelvic
Discontinuity

Appendix

A Step-Wise Algorithmic Approach to Challenging Revisions

While other algorithmic approaches may be used to discuss acetabular revision, this brochure uses Paprosky's classification of acetabular defects to explain the usage of *Trabecular Metal* Acetabular Revision System Components. This approach provides preoperative indications to predict

defects and solutions intraoperatively. It is based on the severity of bone loss and the ability to obtain cementless fixation for a given bone-loss pattern.¹⁶ This system can be used as a guide to maximize contact between the host bone and the *Trabecular Metal* Components, thus optimizing mechanical stability.

Paprosky Classification¹

Defect Type	Defect Characteristics
I	Acetabular rim, anterior column, and posterior column intact and supportive; small, local, contained defects
IIA	Moderate superomedial migration <3cm; >50% host-bone contact
IIB	Moderate superolateral migration <3cm; >50% host-bone contact
IIC	Isolated medial migration, medial to Kohler's line; intact rim
IIIA	Severe superolateral migration >3cm; 40-60% host-bone contact; inadequate stability; defect <1/2 circumference
IIIB	Severe superomedial migration; <40% host-bone contact; inadequate stability; medial to Kohler's line; risk of pelvic discontinuity
Pelvic Discontinuity	Partial or complete fracture

Reconstruction Options

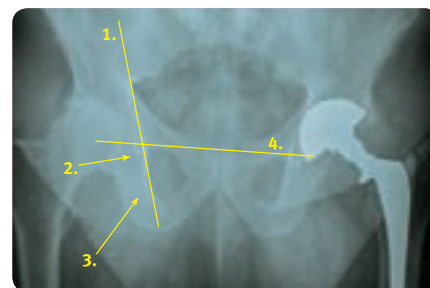
The integrity of the host-bone stock determines the reconstruction option available:

- Completely supportive acetabulum (ingrowth likely)—*Trabecular Metal* Revision Shell
- Partially supportive acetabulum (ingrowth possible)—*Trabecular Metal* Revision Shell with Augments
- Non-supportive (ingrowth unlikely)—*Trabecular Metal* Revision Shell with Buttress Augments and/or Cage

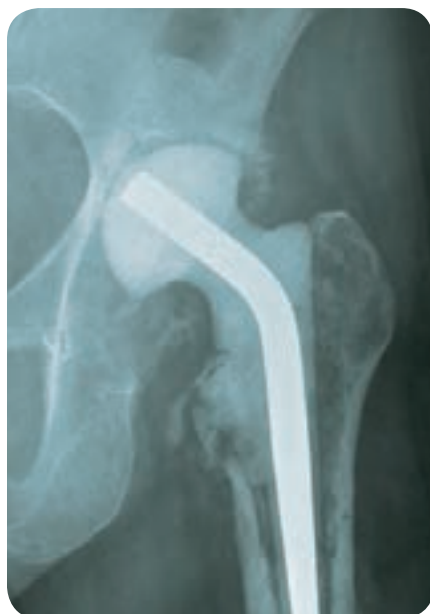Four Landmarks

Indications for component revision are dependent upon four radiographic criteria:

1. **Kohler's Line**—integrity of medial wall and superior anterior column
2. **Acetabular Tear Drop**—integrity of medial wall and inferior portion of anterior and posterior column
3. **Ischial Lysis**—integrity of posterior wall and posterior column
4. **Vertical Migration**—integrity of superior dome



Type I & Type II Defects



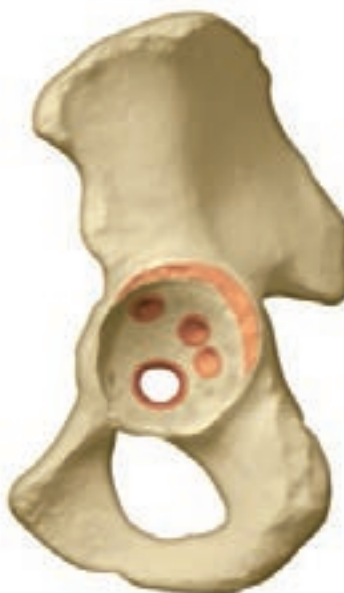Radiograph of Defect

Type I Defect

Kohler's Line: Intact
Tear Drop: Intact
Ischial Lysis: Minimal to none
Vertical Migration: Minimal to none

Type IIA Defect

Kohler's Line: Intact
Tear Drop: Violated
Ischial Lysis: Mild to moderate
Vertical Migration: Minimal to none



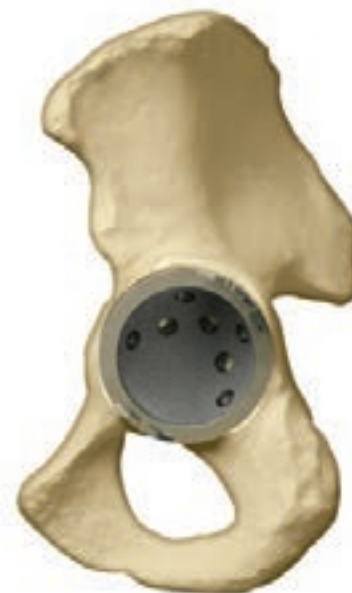Example of Defect

Type IIB Defect

Kohler's Line: Intact
Tear Drop: Intact
Ischial Lysis: Mild
Vertical Migration: $<3\text{cm}$

Type IIC Defect

Kohler's Line: Moderately violated
Tear Drop: Moderate lysis
Ischial Lysis: Minimal
Vertical Migration: Minimal to none



Algorithmic Repair

Solution

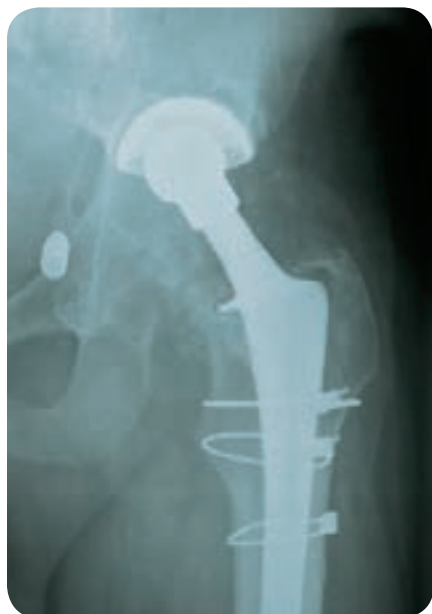Trabecular Metal Revision Shell and
Longevity® Highly Crosslinked Poly-
ethylene Liner

- Designed to prevent backside micromotion
- Cement secures screws
- Isoelastic loading of bone
- Cemented *Longevity* Highly Crosslinked Polyethylene Liners with large-diameter heads, up to 40mm, for additional joint stability and range of motion

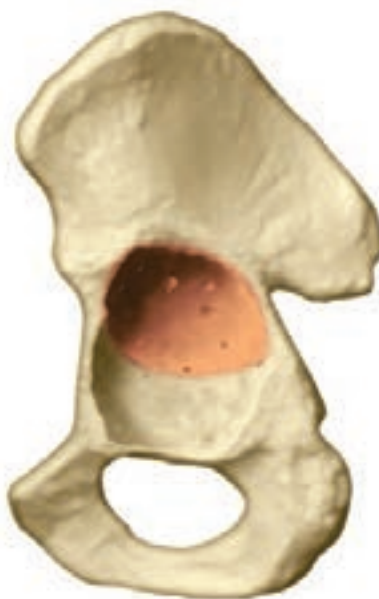

Appendix

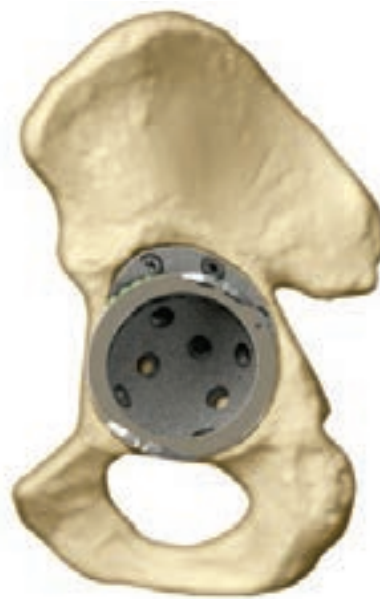Type IIIA—Cavitary Defect



Radiograph of Defect



Example of Defect



Algorithmic Repair

Type IIIA Cavitary Defect

Kohler's Line: Intact

Tear Drop: Minimal lysis

Ischial Lysis: Minimal

Vertical Migration: >3cm

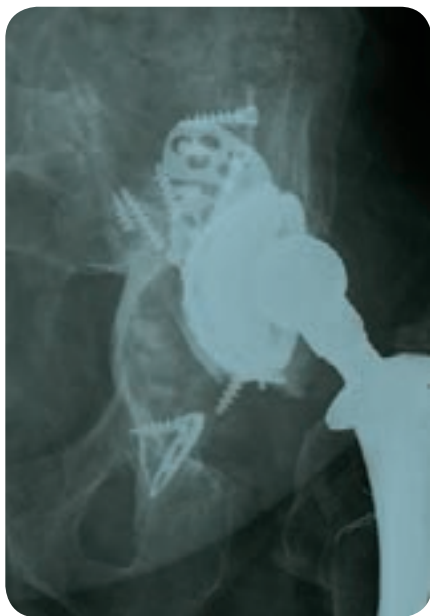Solution

Trabecular Metal Augment in oblong cup position^{2,16-18}

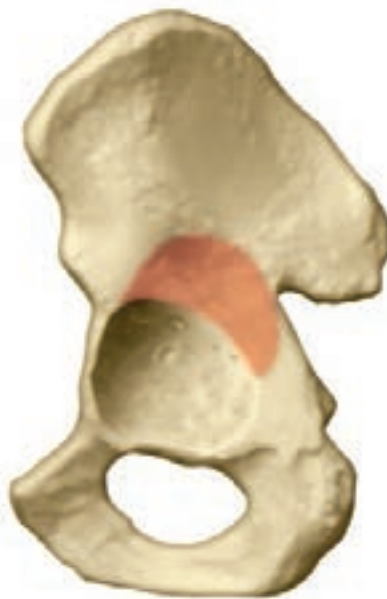- Uses the *Trabecular Metal* Augment to fill the superior bone void and restore head center to natural anatomic position
- Cementing the *Trabecular Metal* Revision Shell to the augment creates a monolithic construct



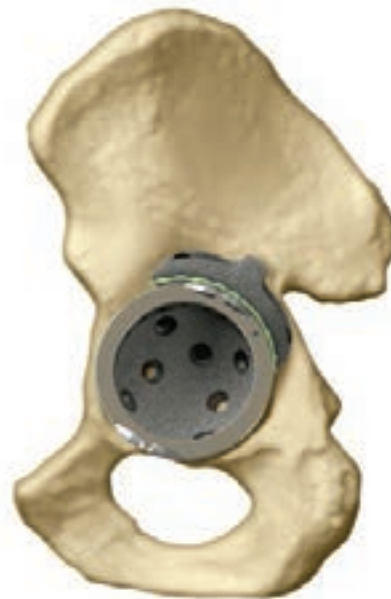Type IIIA—Segmental Defect



Radiograph of Defect



Example of Defect



Algorithmic Repair

Type IIIA Segmental Defect

Kohler's Line: Moderately violated but intact

Tear Drop: Minimal lysis

Ischial Lysis: Mild

Vertical Migration: $>3\text{cm}$

Solution

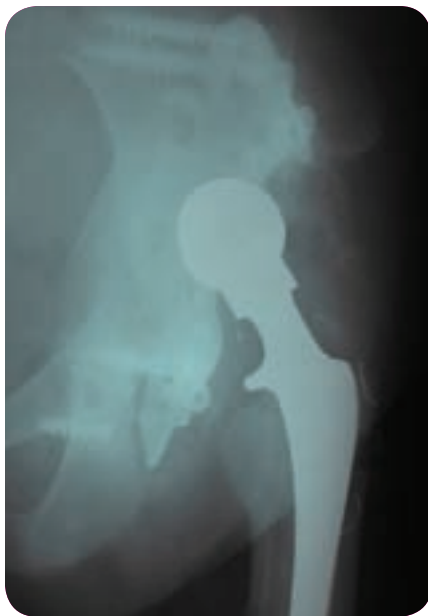
Trabecular Metal Augment in flying buttress position^{2,16-18}

- Uses the *Trabecular Metal Augment*, inverted, as a load-bearing structural support to replace the missing acetabular rim
- Cementing the *Trabecular Metal Revision Shell* to the augment creates a monolithic construct

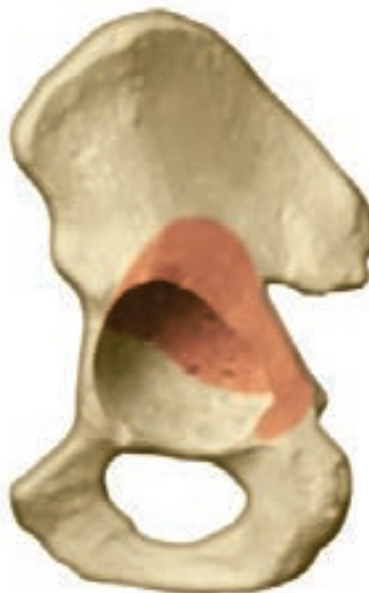

Appendix

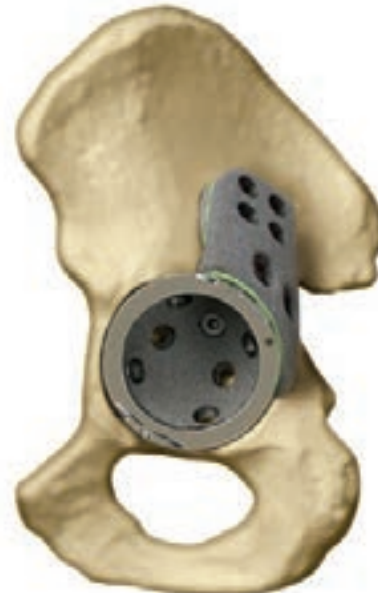Type IIIA—Extensive Segmental Defect



Radiograph of Defect



Example of Defect



Algorithmic Repair

Type IIIA Extensive Segmental Defect

Kohler's Line: Intact

Tear Drop: Minimal lysis

Ischial Lysis: Mild

Vertical Migration: >3cm

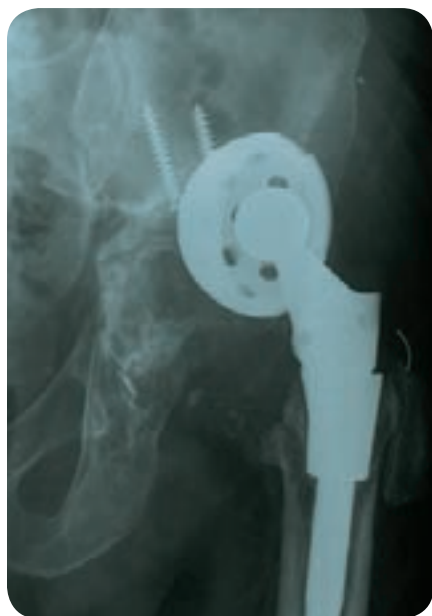Solution

Trabecular Metal Buttress Augment

- *Trabecular Metal* Buttress Augment provides a superior step for placement against the ilium and is an alternative to allografts, which are expensive and tend to resorb
- *Trabecular Metal* Shim Augments are available to supplement the fit of the superior flange of the buttresses onto the ilium
- Cementing the *Trabecular Metal* Revision Shell to the augment creates a monolithic construct



Type IIIB—Contained Medial Defect



Radiograph of Defect

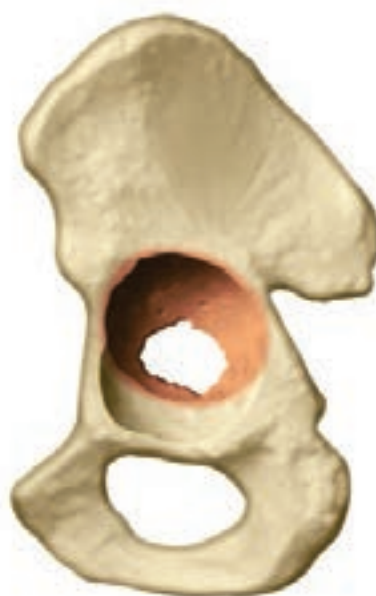Type IIIB Medial Defect

Kohler's Line: Violated

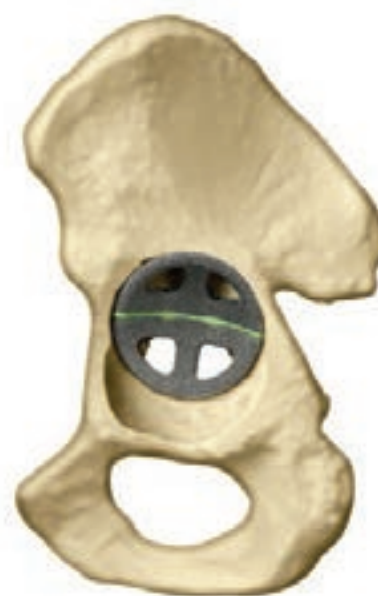Tear Drop: Violated, significant lysis

Ischial Lysis: Severe

Vertical Migration: >3cm



Example of Defect

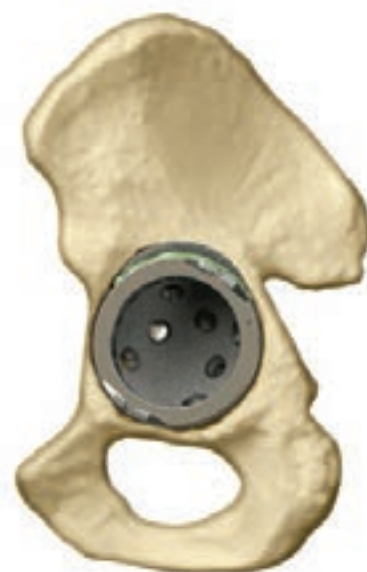

Algorithmic Repair Step 1

Solution

Trabecular Metal Augments in footings position^{2,16-18}

- *Trabecular Metal* Augments sized to fit defect, providing a foundation for the shell and filling voids from medial and/or superior defects
- Cementing the *Trabecular Metal* Revision Shell to the augments creates a monolithic construct

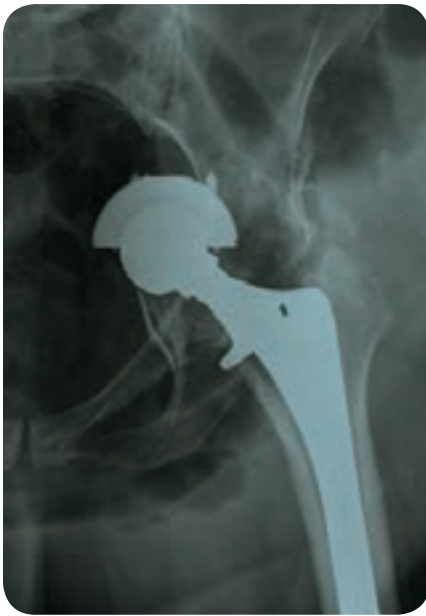

Algorithmic Repair Step 2

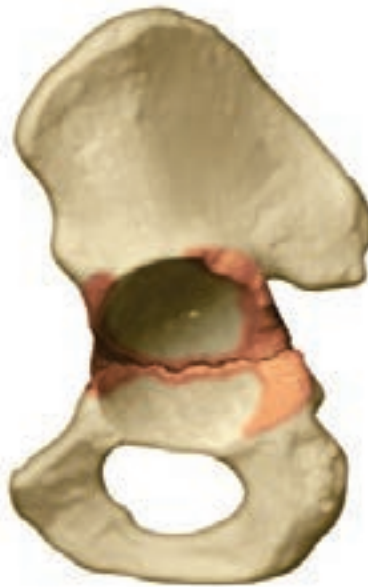

Appendix

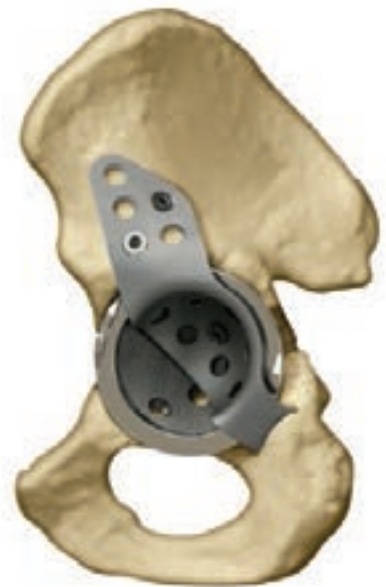Pelvic Discontinuity



Radiograph of Defect



Example of Defect



Algorithmic Repair

Pelvic Discontinuity

- Superior aspect of pelvis is separated from the inferior aspect as a result of bone loss or an acetabular fracture

Solution

Cup-Cage Construct

- The Cage spans the acetabular defect and provides mechanical stability until biological ingrowth occurs within the *Trabecular Metal* Revision Shell
- Used in situations where the *Trabecular Metal* Revision Shell alone does not provide adequate stability
- The *Trabecular Metal* Revision Shell provides potential for bone ingrowth and long-term fixation
- Three components—shell, cage, and liner—cemented together create a monolithic construct



References

1. Paprosky W, Perona P, Lawrence J. Acetabular defect classification and surgical reconstruction in revision arthroplasty. A 6-year follow-up evaluation. *J Arthroplasty*, 1994;9:33-44.
2. Lewallen DG, et al., Revision hip arthroplasty with porous tantalum augments and acetabular shells. Scientific Exhibition: 73rd Annual Meeting of the American Academy of Orthopaedic Surgeons; Chicago, IL, 2006
3. Biomet Brochure Y-BMT-977/011507/M
4. Depuy Brochure 7.5M1007 0612-38-506
5. Stryker Tritanium Primary Acetabular System Ad, 2008. Stryker Test Report RD-08-000: Evaluation of Bone Response to Porous Surfaces Using a Canine Total Hip Model.
6. Bobyn J, Stackpool G, Hacking S, Tanzer M, Krygier J. Characteristics of bone in-growth and interface mechanics of a new porous tantalum biomaterial. *J Bone Joint Surg*, 1999;81-B(5):907-914.
7. Bobyn J, Hacking S, Krygier J, Chan S, Toh K, Tanzer M. Characterization of a new porous tantalum biomaterial for reconstructive surgery. Scientific Exhibition: 66th Annual Meeting of the American Academy of Orthopaedic Surgeons; Feb. 4-8, 1999; Anaheim, CA.
8. Bobyn J, Toh K, Hacking S, Tanzer M, Krygier J. Tissue response to porous tantalum acetabular cups—a canine model. *J Arthroplasty*, 1999;14(3): 347-354.
9. Zhang Y, et al., Interfacial frictional behavior: cancellous bone, cortical bone, and a novel porous tantalum biomaterial. *J Musculoskeletal Res*. 1999; 3(4): 245-251
10. Unger AS, et al., Evaluation of a porous tantalum uncemented acetabular cup in revision total hip arthroplasty: clinical and radiological results of 60 hips. *J Arthroplasty*. 20(8); 2005: 1002-1009
11. Levine B. A new era in porous metals: applications in orthopaedics. *Advanced Engineering Materials*. August 2008; 10(9): 788-792
12. Macheras GA et al., Eight to Ten-Year Clinical and Radiographic Outcome of a Porous Tantalum Monoblock Acetabular Component, *JOA* Vol. 00 No. 02008, In Press
13. Lewis, R, et al., Monoblock Trabecular Metal Acetabulum – Two to Five Year Results, 70th Annual Meeting of the American Academy of Orthopaedic Surgeons, New Orleans, LA, February 5-9, 2003
14. Gruen T, et al., Radiographic evaluation of a non-modular acetabular cup: a 2- to 5-year multi-center study. Scientific Exhibit: 71st Annual Meeting of the American Academy of Orthopaedic Surgeons; San Francisco, CA, 2004
15. Gruen TA, et al., Radiographic evaluation of a monoblock acetabular component: a multicenter study with 2- to 5-year results. *J Arthroplasty*. April 2005; 20(3)
16. Weeden, SH, et al., The Use of Tantalum Porous Metal Implants for Paprosky Type 3A and 3B Implants, *J Arthroplasty*. 2007; 22(6) (suppl 2): 151-155
17. Scott M. Sporer, MD, MS, and Wayne G. Paprosky, MD, FACS; Acetabular Revision Using a Trabecular Metal Acetabular Component for Severe Acetabular Bone Loss Associated With a Pelvic Discontinuity; *J Arthroplasty* Vol. 21 No. 6 Suppl. 2 2006.
18. Paul F. Lachiewicz MD, Elizabeth S. Soileau BSN; Tantalum Components in Difficult Acetabular Revisions; *Clin Orthop Relat Res* (2010) 468:454–458 DOI 10.1007/s11999-009-0940-5.
19. Lakstein D, Backstein D, Safir O, Kosashvili Y, Gross A. “Trabecular Metal Cups for Acetabular Defects with 50% or Less Host Bone Contact.” *Clin Orthop Relat Res*. 2009; 467(9):2318-2324.
20. Nakashima, Yasuharu, et al. “Clinical and radiographic evaluation of total hip arthroplasties using porous tantalum modular acetabular components: 5-year follow-up of clinical trial.” *Modern Rheumatology*. 2013;23(1):112-118.
21. Simon, Jean-Pierre and Bellemans, Johan. “Clinical and radiological evaluation of modular trabecular metal acetabular cups: Short-term results in 64 hips.” *Acta Orthop. Belg*. 2009; 75:623-630.

Zimmer Trabecular Metal Acetabular Revision System

Approach Acetabular Revision Cases with Confidence.



Easy to Use

No structural allograft preparation • One comprehensive modular system

Durable

No resorption issues • Potential for biologic in-growth

Proven Technology

17+ years of clinical history • Full range of revisions successfully treated

This documentation is intended exclusively for physicians and is not intended for laypersons. Information on the products and procedures contained in this document is of a general nature and does not represent and does not constitute medical advice or recommendations. Because this information does not purport to constitute any diagnostic or therapeutic statement with regard to any individual medical case, each patient must be examined and advised individually, and this document does not replace the need for such examination and/or advice in whole or in part. Please refer to the package inserts for important product information, including, but not limited to, contraindications, warnings, precautions, and adverse effects.

The CE Mark is valid only if it is also printed on the Product Label.

Contact your Zimmer representative or visit us at www.zimmer.com

